

# Recurrent pterygium resection associated to fibrin membrane graft: report of two cases

## *Resseção do pterígio recorrente associada ao enxerto de membrana fibrina: relato de dois casos.*

Isabel Mogollón Giralt<sup>1</sup> <https://orcid.org/0000-0002-9047-1441>  
Ana Boto de los Bueis<sup>1</sup> <https://orcid.org/0000-0002-9683-2025>  
Almudena del Hierro Zarzuelo<sup>1</sup> <https://orcid.org/0000-0003-2686-7588>  
José Vicente Dabad Moreno<sup>1</sup> <https://orcid.org/0000-0002-3467-3356>  
Rafael Montejano Milner<sup>2</sup> <https://orcid.org/0000-0002-2288-7285>  
Borja de la Sen Corcuera<sup>3,4</sup> <https://orcid.org/0000-0001-9779-8979X>

### ABSTRACT

*We propose a novel surgical technique in cases of aggressive recurrent pterygium non-subsidiary of treatment with conjunctival autografts or antimetabolites. Two presented cases were treated with surgical excision and a sutured plasma rich in growth factors membrane (mPRGF) followed by rich in growth factors (PRGF) eye drops treatment. After surgery, dexamethasone, tobramycin and PRGF eye drops were prescribed for 6 weeks. After a 12-month and 3-year post-surgical follow-up respectively, treated eyes with mPRGF did not present relapse, and visual acuity improved in both cases. No ocular complications, pain, eye discomfort nor other symptoms were observed. The combined use of PRGF eye drops and mPRGF seems an effective and safe therapy for recurrent pterygium.*

**Keywords:** Pterygium; Recurrence; Platelet-rich fibrin; Platelet-rich plasma; Ophthalmic solutions; Tissue engineering

### RESUMO

Nós propomos uma nova técnica cirúrgica em casos de pterígio agressivo recorrente não subsidiário de tratamento com autoenxertos conjuntivais ou antimetabólitos. Dois casos foram tratados com excisão cirúrgica e um plasma suturado rico em membrana de fatores de crescimento (mPRGF), seguido de tratamento com colírios ricos em fatores de crescimento (PRGF). Após a cirurgia, foram prescritos colírios de dexametasona, tobramicina e PRGF por 6 semanas. Após 12 meses e 3 anos de acompanhamento pós-cirúrgico respectivamente, os olhos tratados com mPRGF não apresentaram recidiva e a acuidade visual melhorou nos dois casos. Não foram observadas complicações oculares, dor, desconforto ocular ou outros sintomas. O uso combinado de colírios de PRGF e mPRGF parece uma terapia eficaz e segura para o pterígio recorrente.

**Descritores:** Pterígio; Recidiva; Fibrina rica em plaquetas; Plasma rico em plaquetas; Soluções oftálmicas; Engenharia tecidual

<sup>1</sup>Ophthalmology Department, IdiPAZ, La Paz University Hospital, Madrid, Spain.

<sup>2</sup>Ophthalmology Department, Príncipe de Asturias University Hospital, Alcalá de Henares, Madrid, Spain.

<sup>3</sup>University Institute for Regenerative Medicine and Oral Implantology (UIRMI), Vitoria, Spain.

<sup>4</sup>Biotechnology Institute (BTI), Vitoria, Spain.

Institution where the work was done: Hospital Universitario La Paz

**Conflicts of interest:** BDLS is a scientist at BTI Biotechnology Institute.

Received for publication 29/4/2019 - Accepted for publication 11/1/2021.



## INTRODUCTION

**P**terygium is a wing-like neof ormation of fibrovascular tissue derived from the conjunctiva over the cornea. Classically it has been defined as an elastotic degeneration caused by ultraviolet radiation damage on corneal limbal cells. Pathogenesis of pterygia has been extensively reviewed by Di Girolamo et al.<sup>(1)</sup>, standing out the release of proinflammatory cytokines and growth factors as TGF- $\beta$  of the conjunctiva with increase and activation of local fibroblasts. Some review consider a tumor-like proliferative disorder with mutation of the tumor suppressor p53 protein and increase in secondary angiogenesis.

Recurrence, which entails chronic inflammation, requires aggressive management. In order to reduce the relapse rate, simple excision or naked sclera techniques have been abandoned (recurrences up to 89% in primary pterygium),<sup>(2)</sup> using instead a free or rotary conjunctival autograft (CAU) after excision (recurrences up to 33.3% in recurrent pterygium).<sup>(3)</sup>

Other therapies have been proposed to prevent relapse, including mitomycin C (MMC),<sup>(4)</sup> 5-fluorouracil (5-FU),<sup>(5)</sup> beta radiation with strontium-90 (Sr-90),<sup>(6)</sup> X-Ray,<sup>(7)</sup> excimer laser<sup>(8)</sup>, amniotic membrane (AM),<sup>(9)</sup> anti-vascular endothelial growth factor (VEGF) agents<sup>(5)</sup> and limbal-conjunctival autograft (LCAG).<sup>(10)</sup>

In the protocol of preferential clinical practice of the Spanish Society of Ophthalmology of pterygium surgery, LCAG is contemplated for recurrences, presenting a lower rate of recurrence compared to CAU or AM graft. Peripheral lamellar keratoplasty is proposed in case of extensive fibrosis, marked symblepharon or corneal thinning.<sup>(11)</sup>

Recently, plasma rich in growth factors fibrin membrane (mPRGF) has successfully been employed as adjuvant treatment in ocular surface disorders surgery, based on the regenerative, anti-inflammatory, antifibrotic and bactericidal characteristics of PRGF.<sup>(12,13)</sup> However, only one case of non-recurrent (primary) pterygium surgery has been described until date with this technique.<sup>(12)</sup>

Hereby, we present two patients with severe recurrent pterygium treated by pterygium excision followed by mPRGF placement and PRGF ophthalmic eye drops treatment.

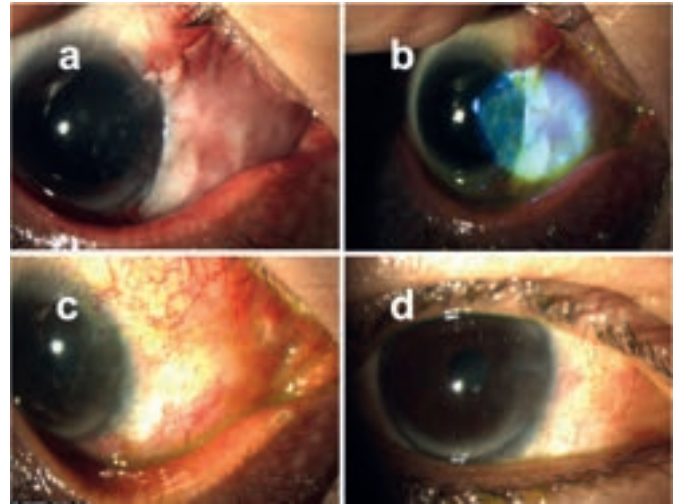
### Case report

#### Case 1

The first case was a 45-year-old patient with relapsed nasal pterygium in the right eye (OD), surgically intervened by excision and CAU 3 years previously. Best corrected visual acuity (BCVA) was 20/60, with -8.75 diopters (D) of astigmatism at 174° attributable to pterygium and +7.25D of hyperopia. Biomicroscopic (BMC) evaluation revealed a recurrent pterygium with translucency grade 3,<sup>(14)</sup> 2.7 mm of corneal invasion (CI), 6.1 mm of limbal base (LB) and caruncular traction (CT) grade 1.<sup>(15)</sup>

In absence of response to 9 biweekly injections of 0.1 mL subconjunctival 50mg/mL 5-FU, surgical intervention was proposed.

To obtain the autologous fibrin graft and the eye drop treatment, an Endoret-PRGF kit<sup>®</sup> and equipment (BTI Biotechnology Institute, Vitoria, Spain) was used following the manufacturer instructions. 81 mL of the patient's blood was extracted with sodium citrate as an anticoagulant. The blood was subsequently centrifuged at 580 g at room temperature for 8 mins. The fraction 2 (F2) was defined as the 2 mL of plasma above the leukocyte layer



**Figure 1:** shows patients slit lamp biomicroscopy one day (a), one week (b), one month (c) and 3 months (d) after surgery. Note the resolution of the pterygium with no recurrence.

and fraction 1 (F1) was defined as the remaining plasma above F2.

After its collection, 5 mL of F2 was activated with the calcium based Endoret activator<sup>®</sup> and then incubated at 37°C for 20 mins. Once the fibrin clots were formed, they were pressed for 10 seconds in a shaping press, obtaining a 500  $\mu$ m thick mPRGF.<sup>(12)</sup> For the eye drop treatment 12 mL of the remaining plasma was collected combining both F1 and F2. After its activation PRGF was incubated at 37°C for 40 min and then filtered and aliquoted.<sup>(16)</sup>

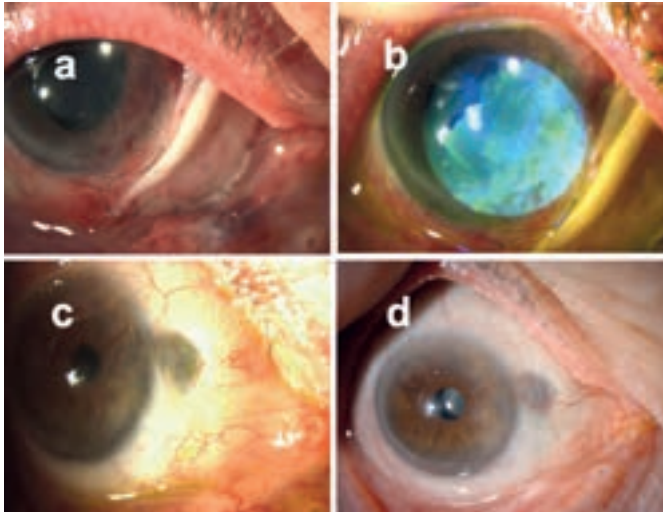
Under retrobulbar anesthesia, the surgery consisted of the removal of the pterygium followed by the suture of the 500 $\mu$ m thick, 7x14.5mm mPRGF graft with 10-0 nylon. Subsequently, 8mg of subconjunctival acetamide triamcinolone was injected. Postoperatively, 0.3% tobramycin and 0.1% dexamethasone eye drops were prescribed in a tapering dose.

A week after the intervention, good membrane positioning and positive fluorescein (F) staining of the graft were observed. Epithelization and membrane reabsorption was completed on the mPRGF area at the 3rd week visit and stitches were removed. Given serological negativity results of the blood samples taken, treatment with PRGF eye drops was prescribed 4 times a day for 6 weeks. At 12 months, BMC showed complete conjunctival bed healing, stable in subsequent revisions (Figure 1). BCVA at the end of the follow-up was 20/20.

#### Case 2

The second case was a 70-year-old male with relapsed pterygium in OD after excision and CAU 9 years previously. BCVA was 20/30 with a cylinder of -2.75D at 67°. BMC showed pterygium of grade 3 translucency; 3.8 mm of CI, 8 mm of LB, and grade 3 CT. In addition, BMC revealed superior bulbar conjunctiva mild fibrosis, scleromalacia in upper nasal area and mild superior limbal deficiency. As increased secondary corneo-conjunctival complications to MMC or 5-FU local application have been described in patients with previous ocular surface disorders<sup>(17,18)</sup>, these techniques were dismissed and mPRGF treatment was proposed.

To obtain the autologous fibrin graft and eye drop treatment, an Endoret-PRGF kit<sup>®</sup> and equipment (BTI Biotechnology Institute, Vitoria, Spain) was used following the manufacturer instructions. 81 mL of the patient's blood was extracted with sodium citrate as an anticoagulant. The blood was subsequently



**Figure 2:** Patients slit lamp biomicroscopy one day (a), week (b), month (c) and 3 years (d) after surgery. Note the resolution of the pterygium with no recurrence and underlying scleromalacia stability

centrifuged at 580 g at room temperature for 8 mins.

The fraction 2 (F2) was defined as the 2 mL of plasma above the leukocyte layer and fraction 1 (F1) was defined as the remaining plasma above F2.

After its collection, 5 mL of F2 was activated with the calcium based Endoret activator® and then incubated at 37°C for 20 mins. Once the fibrin clots were formed, they were pressed for 10 seconds in a shaping press, obtaining a 100 µm thick mPRGF<sup>(12)</sup>. For the eye drop treatment 12 mL of the remaining plasma was collected combining both F1 and F2. After its activation PRGF was incubated at 37°C for 40 min and then filtered and aliquoted.<sup>(16)</sup>

Under retrobulbar anesthesia, pterygium was excised, the 100µm thick, 15x10.5mm mPRGF graft was sutured with 10-0 nylon and 8mg subconjunctival acetone triamcinolone was injected.

One week after the surgery, the BMC showed incomplete epithelialization with congestive vessels. Treatment with PRGF eye drops 4 times a day was established. At 2 weeks, complete reabsorption of mPRGF was observed and stitches were removed. In posterior explorations the evolution was favorable. Three years after surgery no signs of corneal nor conjunctival recurrence were observed (Figure 2) and BCVA was 20/20. The evolution is summarized in figure 2.

## DISCUSSION

Postsurgical pterygium recurrence is a dreaded outcome which requires aggressive management. Many medical and surgical techniques have been used in order to treat recurrent pterygium, standing out among them CAU, AM, nasal and oral mucosal grafts, MMC, 5-FU and bevacizumab.

The advantages of CAU are its epithelializing and anti-inflammatory character with low concentration of inflammatory cytokines. In recurrent pterygium this technique may often require larger grafts due to the larger defect left after fibrous and tight conjunctiva and Tenon removal. In absence of healthy conjunctiva, amniotic membrane (AM) or extraocular mucosa have been used as a substitute graft. AM promotes healing and also suppresses fibroblasts expression of TGF-β, inhibiting the development of myofibroblasts which are the precursors of the

pterygium.<sup>(19,20)</sup> However, it has higher recurrence rates compared to CAU (recurrences rates between 3.8-40.9%) and higher cost.<sup>(21)</sup> Nasal mucosal grafts,<sup>(22)</sup> and autologous cultivated oral mucosal epithelial transplantation<sup>(23)</sup> have been used, with varying reported success rates.

Likewise, multiple substances have been used as primary approach or adjuvant treatment to reduce or to treat recurrences, among which, MMC<sup>(4)</sup> and 5-FU<sup>(5,24)</sup> stand out. Recurrence rates up to 27.3% and 8.7% have been reported in relapsed pterygium after 0.02% MMC and 50 mg/mL 5-FU respectively<sup>(4,5,25)</sup> but both drugs are not free of sclera or ocular surface complications. Besides, after verifying overexpression of VEGF in recurrent pterygium<sup>(1,26,27)</sup>, the use of subconjunctival bevacizumab 0.05% is being investigated, with statistically significant results in a meta-analysis performed by Sun and collaborators in 2018.<sup>(27)</sup>

Nonetheless, the techniques above described are not exempt from complications or risk of failure and new ones are being studied. In this report, we present a new therapeutic option for two recurrent pterygium patients: the bimodal use of PRGF as membrane and drops. PRGF is a standardized and optimized technology for tissue repair and regeneration consisting on the preparation of several autologous formulations obtained from the patient's own blood, including growth factors-rich eye drops and a biomimetic and elastic fibrin membrane (mPRGF).<sup>(13)</sup>

mPRGF has been used in different medical fields such as oral maxillofacial surgery, orthopedics or dermatology since 1999.<sup>(12,13)</sup> In the ophthalmic field numerous previous studies reported that the use of PRGF eye drops is well tolerated.<sup>(13)</sup> Similarly, these resources (mPRGF and PRGF drops) could be used for recurrent pterygium surgery, based on their capability to induce tissue regeneration and its anti-inflammatory and its antifibrotic potential.

In the presented cases, PRGF treatment was proposed instead of a second CAU because of the presentation with fleshy pterygium grade 3 translucency, which has been described as a significant risk factor for recurrence after CAU.<sup>(14)</sup> A second CAU was also dismissed because in the first case the inflammation didn't respond to sequential 5-FU injections, and the second case presented a highly damaged ocular surface.

On the other hand, mPRGF presents advantages compared to AM as its faster clinical availability and autologous origin.

The speed of membrane reabsorption and reepithelialization of the mPRGF may depend on different factors. We propose the grade of inflammation (either previously existing or concomitant and produced by surgery) and physical and biological mPRGF characteristics as main factors involved in membrane processing.

Firstly, in an experimental model of conjunctiva and Tenon excision followed by the placement of a non-standardized, non-commercial fibrin membrane, the fibrin membrane was completely degraded and almost all the defective zone epithelialized on day 7 after placement. Along with this, there was a severe inflammatory reaction from the 1st day after surgery, statistically significant compared to control (bare sclera), which diminished from day 3 until disappearing on day 28. This was hypothesized to be most likely related to the presence of leukocytes and cytokines in the fibrin network used during this study.<sup>(28)</sup> Conversely, as mPRGF is a leukocyte free formulation, lower levels of pro-inflammatory cytokines should be found.

Absence of pro-inflammatory cytokines in PRGF scaffolds has been reported preclinically in an "in vitro" study whilst added leukocyte released interleukin 1β (IL-1β) triggering inflammatory response and stimulating matrix metalloproteinases (MMPs)

production, leading to a faster degradation of the fibrin in the extracellular matrix.<sup>(29)</sup>

Secondly, aiming a lower risk of inflammation, nylon instead of polyglactine absorbable sutures were used.<sup>(30)</sup>

Thirdly, in our patients, mPRGF reabsorption speed might be related to the mPRGF thickness. Until date, mPRGF thickness depends on the pressure exerted manually on the shaping press device and on its orientation: in the first case, the 500µm thick mPRGF reabsorbed in 3 weeks whilst in the second case, the 100 µm thick mPRGF reabsorbed in 2 weeks. Nonetheless, there are no studies evaluating the correlation of this particular factor on the surgical outcome yet. These results are similar to the previously reported by Sanchez-Avila et al. in a case of primary pterygium, with mPRGF complete reabsorption after 15 days and complete defect healing after 4 weeks.<sup>(12)</sup>

Finally, regarding mPRGF's anti-fibrotic properties, the TGF-β inhibition has been reported in several preclinic studies. This finding suggests a promising role of PRGF in myofibroblast modulation in ocular surface tissues, especially for those ocular conditions in which fibrotic response plays a main role such as pterygium, corneal haze formation or cicatrizing conjunctivitis among others.<sup>(31-33)</sup>

For all these reasons, we found the choice of PRGF graft instead of fibrin graft, nylon suture instead of polyglactin suture and pre and post-surgical inflammation regulation as crucial elements. Further studies are needed in order to optimizing the technique, considering graft thickness, surgical sutures or concomitant anti-inflammatory treatment.

In the presented cases there was no evidence of corneal-conjunctival recurrence, granuloma, symblepharon formation or pain during follow-up. In addition, BCVA markedly improved in both cases.

## CONCLUSION

Multiple studies have shown the effectiveness of mPRGF in corneo-conjunctival pathologies. An innovative application can be made in recurrent pterygium treatment due to its regenerative, antifibrotic and anti-inflammatory effects. Its advantages include its standardized procurement process, surgical technique (similar to other currently used techniques), adjuvant treatment with PRGF eye drops and its autologous nature avoiding the risk of rejection and pathogen transmission.

We believe that bimodal use of PRGF (membrane and drops) offers an alternative option for recurrent pterygium in cases of aggressive recurrence or limited residual conjunctiva and partial limbal deficiency.

To date, to the best of our knowledge and examination of the relevant literature, this is the first report that informs about its use for this indication. Due to low number of patients, further studies are required to confirm the efficacy and safety of this technique.

**Acknowledgment:** The authors would like to thank Cristina Torres Giralt for her support with the Portuguese grammar.

## REFERENCES

1. Di Girolamo N, Chui J, Coroneo MT, Wakefield D. Pathogenesis of pterygia: role of cytokines, growth factors, and matrix metalloproteinases. *Prog Retin Eye Res.* 2004;23(2):195–228.

2. Kaufman SC, Jacobs DS, Lee WB, Deng SX, Rosenblatt MI, Shtein RM. Options and adjuvants in surgery for pterygium: a report by the American Academy of Ophthalmology. *Ophthalmology.* 2013;120(1):201–8.
3. Bilge AD. Comparison of conjunctival autograft and conjunctival transposition flap techniques in primary pterygium surgery. *Saudi J Ophthalmol.* 2018 ;32(2):110–3.
4. Khan FA, Niazi SP. Effect of pterygium morphology on recurrence with preoperative subconjunctival injection of mitomycin-C in primary pterygium surgery. *J Coll Physicians Surg Pak.* 2019;29(7):639–43.
5. Bekibele CO, Sarimiye TF, Ogundipe A, Olaniyan S. 5-Fluorouracil vs avastin as adjunct to conjunctival autograft in the surgical treatment of pterygium. *Eye (Lond).* 2016;30(4):515–21.
6. Viani GA, Stefano EJ, De Fendi LI, Fonseca EC. Long-term results and prognostic factors of fractionated strontium-90 eye applicator for pterygium. *Int J Radiat Oncol Biol Phys.* 2008;72(4):1174–9.
7. Willner J, Flentje M, Lieb W. Soft X-ray therapy of recurrent pterygium—an alternative to 90Sr eye applicators. *Strahlenther Onkol.* 2001;177(8):404–9.
8. Chen D, Liu X, Long Q, Wang Z, Li Y. Effects of excimer laser phototherapeutic keratectomy in limbal-conjunctival autograft transplantation for recurrent pterygium: a retrospective case control study. *BMC Ophthalmol.* 2019;19(1):238.
9. Rosen R. Amniotic membrane grafts to reduce pterygium recurrence. *Cornea.* 2018;37(2):189–93.
10. Chen R, Huang G, Liu S, Ma W, Yin X, Zhou S. Limbal conjunctival versus amniotic membrane in the intraoperative application of mitomycin C for recurrent pterygium: a randomized controlled trial. *Graefes Arch Clin Exp Ophthalmol.* 2017;255(2):375–85.
11. Iradier Urrutia MT, Palmero Fernández L, Bañeros Rojas P, editors. *Cirugía del pterigion. Protocolo de práctica clínica preferente.* Madrid: Sociedad Española de Oftalmología; 2017. 45p.
12. Sanchez-Avila RM, Merayo-Llodes J, Riestra AC, Berisa S, Lisa C, Sánchez JA, et al. Plasma rich in growth factors membrane as coadjuvant treatment in the surgery of ocular surface disorders. *Medicine (Baltimore).* 2018;97(17):e0242.
13. Anitua E, Muruzabal F, de la Fuente M, Merayo J, Durán J, Orive G. Plasma rich in growth factors for the treatment of ocular surface diseases. *Curr Eye Res.* 2016;41(7):875–82.
14. Tan DT, Chee SP, Dear KB, Lim AS. Effect of pterygium morphology on pterygium recurrence in a controlled trial comparing conjunctival autografting with bare sclera excision. *Arch Ophthalmol.* 1997;115(10):1235–40.
15. Liu J, Fu Y, Xu Y, Tseng SC. New grading system to improve the surgical outcome of multirecurrent pterygia. *Arch Ophthalmol.* 2012;130(1):39–49.
16. Anitua E, Prado R, Troya M, Zalduendo M, de la Fuente M, Pino A, et al. Implementation of a more physiological plasma rich in growth factor (PRGF) protocol: anticoagulant removal and reduction in activator concentration. *Platelets.* 2016;27(5):459–66.
17. Hovanesian JA, Starr CE, Vroman DT, Mah FS, Gomes JA, Farid M, et al.; ASCRS Cornea Clinical Committee. Surgical techniques and adjuvants for the management of primary and recurrent pterygia. *J Cataract Refract Surg.* 2017;43(3):405–19.
18. Hickey-Dwyer M, Wishart PK. Serious corneal complication of 5-fluorouracil. *Br J Ophthalmol.* 1993;77(4):250–1.
19. Tseng SC, Li DQ, Ma X. Suppression of transforming growth factor-beta isoforms, TGF-beta receptor type II, and myofibroblast differentiation in cultured human corneal and limbal fibroblasts by amniotic membrane matrix. *J Cell Physiol.* 1999;179(3):325–35.
20. Lee SB, Li DQ, Tan DT, Meller DC, Tseng SC. Suppression of TGF-β signaling in both normal conjunctival fibroblasts and pterygial body fibroblasts by amniotic membrane. *Curr Eye Res.* 2000;20(4):325–34.
21. Clearfield E, Hawkins BS, Kuo IC. Conjunctival autograft versus amniotic membrane transplantation for treatment of pterygium: findings from a Cochrane systematic review. *Am J Ophthalmol.* 2017;182:8–17.

22. Chun YS, Park IK, Kim JC. Technique for autologous nasal mucosa transplantation in severe ocular surface disease. *Eur J Ophthalmol*. 2011;21(5):545–51.
23. Prabhasawat P, Ekpo P, Uiprasertkul M, Chotikavanich S, Tesavibul N, Pornpanich K, et al. Long-term result of autologous cultivated oral mucosal epithelial transplantation for severe ocular surface disease. *Cell Tissue Bank*. 2016;17(3):491–503.
24. García Tirado A, Boto de Los Bueis A, Rivas Jara L. Ocular surface changes in recurrent pterygium cases post-operatively treated with 5-fluorouracil subconjunctival injections. *Eur J Ophthalmol*. 2019;29(1):9–14.
25. Bekibele CO, Ashaye A, Olusanya B, Baiyeroju A, Fasina O, Ibrahim AO, et al. 5-Fluorouracil versus mitomycin C as adjuncts to conjunctival autograft in preventing pterygium recurrence. *Int Ophthalmol*. 2012;32(1):3–8.
26. Khalfaoui T, Mkannez G, Colin D, Imen A, Zbiba W, Errais K, et al. Immunohistochemical analysis of vascular endothelial growth factor (VEGF) and p53 expression in pterygium from Tunisian patients. *Pathol Biol (Paris)*. 2011;59(3):137–41.
27. Sun Y, Zhang B, Jia X, Ling S, Deng J. Efficacy and safety of bevacizumab in the treatment of pterygium: an updated meta-analysis of randomized controlled trials. *J Ophthalmol*. 2018;2018:4598173.
28. Can ME, Çakmak HB, Dereli Can G, Ünverdi H, Toklu Y, Hücemenoglu S. A novel technique for conjunctivoplasty in a rabbit model: platelet-rich fibrin membrane grafting. *J Ophthalmol*. 2016;2016:1965720.
29. Anitua E, Zalduendo MM, Prado R, Alkhraisat MH, Orive G. Morphogen and proinflammatory cytokine release kinetics from PRGF-Endoret fibrin scaffolds: evaluation of the effect of leukocyte inclusion. *J Biomed Mater Res A*. 2015;103(3):1011–20.
30. Wong VW, Rao SK, Lam DS. Polyglactin sutures versus nylon sutures for suturing of conjunctival autograft in pterygium surgery: a randomized, controlled trial. *Acta Ophthalmol Scand*. 2007;85(6):658–61.
31. Anitua E, Sanchez M, Merayo-Llodes J, De la Fuente M, Muruzabal F, Orive G. Plasma rich in growth factors (PRGF-Endoret) stimulates proliferation and migration of primary keratocytes and conjunctival fibroblasts and inhibits and reverts TGF-beta1-Induced myodifferentiation. *Invest Ophthalmol Vis Sci*. 2011;52(9):6066–73.
32. Anitua E, Muruzabal F, Alcalde I, Merayo-Llodes J, Orive G. Plasma rich in growth factors (PRGF-Endoret) stimulates corneal wound healing and reduces haze formation after PRK surgery. *Exp Eye Res*. 2013;115:153–61.
33. Anitua E, de la Fuente M, Muruzabal F, Riestra A, Merayo-Llodes J, Orive G. Plasma rich in growth factors (PRGF) eye drops stimulates scarless regeneration compared to autologous serum in the ocular surface stromal fibroblasts. *Exp Eye Res*. 2015;135:118–26.

---

**Corresponding author:**

Isabel Mogollón Giralt  
 c/Juan Nogre Rauch 1, 1<sup>º</sup> izq  
 06005, Badajoz, España